

RECOOP HST ASSOCIATION

UDC 613.32:546.175:616.71-018.44]-092.9

doi: <https://doi.org/10.15407/ubj94.05.069>

EFFECT OF NITRATES ON THE BONE MARROW OF RATS

M. V. DANCHYSHYN[✉], O. V. LOTOTSKA

I. Horbachevsky Ternopil National Medical University, Ukraine;
[✉]e-mail: danchyshyn@tdmu.edu.ua

Received: 28 January 2022; **Revised:** 21 March 2022; **Accepted:** 20 September 2022

Nitrate pollution of groundwater has been increasing in recent years. The aim of this work was to study the morphological features of the bone marrow of rats at the consumption of drinking water with varying nitrate content. The experiment was performed on 2 groups of white female rats of different ages (mature and immature) with 30 individuals each. Both groups were divided into 5 subgroups that differed in the quality of drinking water consumed by rats on their own. In the 30 days study, nitrate was given to rats in drinking water in doses of 50, 150, 250, 500 mg of sodium nitrate per liter. Animals of the control group drank water from the city water supply. The effect of nitrates on the bone marrow of rats was evaluated by morphological analysis. It was found that the consumption of drinking water with nitrates affected erythropoiesis and leukopoiesis, as evidenced by the growth of blasts, lymphocytes, pronormocytes and normocytes, megakaryocytes and eosinophils, displacement of erythrocyte sprout cells. An increase in the neutrophil maturation index indicates delayed neutrophil maturation, increased yield of mature cells from the bone marrow and depletion of the granulocyte lineage. The more pronounced changes were observed in the qualitative and quantitative composition of the components of the erythrocyte sprout. These disorders were dose-dependent with increasing hematotoxic effect of nitrates at doses of 250 and 500 mg/l in the group of immature animals and resulted in changes in the bone marrow, which may further cause the development of pathological processes in an organism.

Key words: nitrates, drinking water, bone marrow of rats, Van Gieson's stain.

Environmental pollution is a global problem. Various chemical and biological contaminants in air, water, food and soil as well as radiation can adversely affect human health [1]. Many organs and systems in the human body are responsible for maintaining homeostasis. However, one of the main and most sensitive organs that responds instantly to changes in the qualitative and quantitative composition of the environment is the bone marrow. It is responsible for the formation of all cellular elements of the blood from the fetal period [2, 3]. In the process of life, the bone marrow is influenced by various exogenous and endogenous factors, which to some extent affect the process of hematopoiesis, causing various disorders [4].

In recent years, there has been increasing information about the global spread of nitrates in water, soil and food. Nitrate levels in our water resources

have increased in many areas of the world largely due to applications of inorganic fertilizer and animal manure in agricultural areas [5, 6].

Nitrates or salts of nitric acid are characterized by a fairly wide range of toxic effects. Their presence in high concentrations in surface and groundwater causes a number of health problems. The toxic effect of nitrates lies in the fact that in the digestive tract they are under the influence of certain types of gastric microorganisms that are reduced to nitrites and, due to oxidation of ferrous to trivalent block. The formation of hemoglobin causes methemoglobinemia, which manifests itself as anemia at any age [7].

Nitrates also inhibit the activity of enzyme systems involved in tissue respiration. In addition, it was found that nitrites in the presence of amines can form N-nitrosamines, which show carcinogenic activity. Considering all studies, the strongest evi-

dence for a relationship between drinking water nitrate ingestion and adverse health outcomes (besides methemoglobinemia) is for colorectal cancer, thyroid disease and neural tube defects [5]. Nitrates in drinking water affect the nervous and cardiovascular systems, the development of embryos [8] and, with systematic entry into the body, can lead to disorders of the endocrine and central nervous system and blood circulation, as well as adversely affect aquatic organisms [9].

As a result of laboratory studies, a hematotoxic effect of nitrate salts at a dose of 100 mg/l on the bone marrow of rats with long-term admission was revealed, which was manifested by a gradual inhibition of hematopoiesis and dysplastic changes in the precursors of cellular blood cells. The detected changes were more characteristic of erythrocyte sprout hematopoiesis, although some deviations from the norm were observed in the process of granulopoiesis and thrombocytopoiesis [10].

Other studies in rats also provided evidence of the adverse effects of nitric acid salts on hematological parameters. Similarly, a significant decrease in hemoglobin, hematocrit and erythrocyte counts has been reported. In addition, the number of leukocytes and lymphocytes have been shown to decrease due to the inability of hematopoietic tissues to produce new leukocytes [11].

The Drinking Water Directive (98/83/EC) and water quality standards in many countries set a maximum allowable concentration (MAC) of nitrate at 50 mg/l. It has been shown that drinking water in excess of the nitrate limit can result in adverse health effects, especially in infants less than two months of age. The general trend of nitrate concentrations in groundwater is summarized as “stable to increasing.” Nitrate drinking water limit values are exceeded in around one-third of the groundwater bodies for which information is currently available. The monitoring of nitrate levels in groundwater at different districts of the Ternopil region showed that exceeding the MAC ranged from 1.1 to 7.3 times or from 55 to 365 mg/l and more [6]. People have been using this water for drinking for many years because nitrates, even in excessive amounts, are not felt by humans.

The objective of this study was to determine the morphological features of the bone marrow of white female rats of different ages under the conditions of consumption of drinking water with nitrates at levels of 50, 150, 250 and 500 mg/l (or in 1, 3, 5 and 10 times more than the MAC) for 30 days.

Materials and Methods

The experiments were performed on 60 outbred white female rats kept on the standard diet of the vivarium, in cages with natural light at a temperature between 20–22°C, with access to food and water that was unrestricted. Experimental animals were divided into 2 groups: 30 outbred mature white female rats aged 6 months with an initial body weight of 180–200 g and 30 outbred immature white female rats aged 2 months with an initial body weight of 60–80 g. Each group of animals was divided into five subgroups: the first subgroup consumed drinking water with a nitrate content of 50 mg/l the second one consumed drinking water with a nitrate content of 150 mg/l, the third subgroup consumed drinking water with a nitrate content of 250 mg/l and the fourth one consumed drinking water with a nitrate content of 500 mg/l. Rats of the control group consumed drinking water from the city water supply.

Aqueous solutions of sodium nitrate (NaNO_3) with concentrations 50, 150, 250, 500 mg/l were prepared from the city water supply system taking into account the background level (11.3 mg/l). Groups were selected by randomization.

The experiments were performed following the principles of bioethics according to “Ethical Guidelines for the Use of Animals in Research” adopted at the First National Congress on Bioethics (Kyiv, 2001) and consistent with the provisions of the “European Convention for the Protection of Vertebrate Animals used for Experimental and other Scientific Purposes” (Strasbourg, 1986) and European Union Directive 2010/63/EU on the protection of animals used for scientific purposes. Euthanasia of animals was performed by bloodletting under thiopental sodium anesthesia 30 days after the start of the experiment.

The study of the structure of the bone marrow was performed by sampling from the sternum. Sampling was performed under thiopental sodium anesthesia. The obtained bone marrow elements were applied to slides and stained with hematoxylin and eosin, according to Van Guise [15]. The bone marrow smears on the microscopic slides were studied using a MICROMed SEO CCAN light microscope and photodocumented using a Vision CCD Camera with a histological image output system. The neutrophil maturation index (NMI), which characterizes the state of the granulocyte sprout, was also calculated [14]. This is the ratio of the percentage

of young elements of the granular series (promyelocytes, myelocytes and metamyelocytes) to the percentage of mature granulocytes (rod and segmental).

Statistical processing of the results was performed using the computer program Excel 2010. The choice of statistical research method was based on the correct distribution of the studied features. Statistical data processing was conducted using the STATISTICA 10 program. The comparison of the attained indexes was performed using the Mann-Whitney U-test. The changes were statistically significant at $P \leq 0.05$.

Results and Discussion

In our studies, a hematotoxic effect of nitrate salts, which depended on their concentration in drinking water, was revealed. In the myelogram, a

differential count of at least 300 cells of all hemopoietic processes was performed with an assessment of the morphology of hemopoietic cells and the results of the myelogram in percent were derived. It should be noted that in immature animals of all experimental groups, the growth of blasts, lymphocytes, pronormocytes and normocytes, megakaryocytes and eosinophils and displacement of erythrocyte germ cells were detected. These are presented in Tables 1 and 2.

In white female rats of different maturity from control groups, that consumed drinking water from a city water supply system with a nitrate concentration of 11.3 mg/l, no statistically significant changes were found in the qualitative and quantitative composition of bone marrow components ($P > 0.05$). Compared to the control group, in both groups of mature and

Table 1. Morphological composition of bone marrow of mature white female rats that consumed drinking water with nitrates (myelogram)

Parameter, %	Group				
	Control	1 st	2 nd	3 rd	4 th
Blast cells	2.67 ± 0.21	3.00 ± 0.37	4.67 ± 1.17	5.33 ± 0.42*	5.67 ± 0.54*
Band cells	8.33 ± 0.42	10.67 ± 0.42	13.33 ± 1.17	15.00 ± 0.73*	16.33 ± 2.20*
Segmented cells	7.76 ± 0.76	10.33 ± 0.76	11.67 ± 0.76	13.33 ± 2.20	21.33 ± 2.84*
Eosinophils	1.67 ± 0.42	2.33 ± 0.20	2.67 ± 0.20	4.0 ± 0.4*	4.67 ± 0.70*
Lymphocytes	23.67 ± 3.66	29.33 ± 7.85	31.0 ± 1.1	32.0 ± 4.91	40.67 ± 4.82
Prolymphocyte	8.33 ± 1.28	9.67 ± 0.92	12.33 ± 3.66	13.67 ± 2.74	15.67 ± 1.38*
Normocyte	11.67 ± 4.70	13.67 ± 1.80	14.0 ± 2.4	15.0 ± 2.7	26.0 ± 2.2*
Pronormocyte	2.33 ± 0.40	4.0 ± 1.3	5.33 ± 0.50	5.33 ± 1.30	7.33 ± 0.90*

*Significant difference ($P < 0.05$) compared to the control group, $M \pm m$, $n = 6$

Table 2. Morphological composition of bone marrow of immature white female rats that consumed drinking water with nitrates (myelogram)

Parameter, %	Group				
	Control	1 st	2 nd	3 rd	4 th
Blast cells	2.33 ± 0.30	2.83 ± 0.50	2.83 ± 0.70	3.67 ± 0.40*	5.83 ± 0.90*
Band cells	13.83 ± 1.90	14.17 ± 1.10	15.67 ± 0.70	16.17 ± 1.20	17.17 ± 3.00
Segmented cells	8.17 ± 0.50	11.17 ± 1.10	12.67 ± 0.30	12.83 ± 2.20	15.83 ± 1.50*
Eosinophils	2.17 ± 0.50	2.83 ± 0.50	3.83 ± 0.70	5.67 ± 1.00*	9.83 ± 0.70*
Lymphocytes	14.17 ± 1.70	22.42 ± 1.80	23.67 ± 3.60	38.67 ± 2.30*	40.0 ± 1.4*
Prolymphocyte	1.97 ± 0.30	2.33 ± 0.20	4.67 ± 1.00*	5.83 ± 1.00*	7.83 ± 1.40*
Normocyte	8.67 ± 1.20	19.67 ± 5.10	21.83 ± 2.90	21.83 ± 3.20	25.67 ± 1.60*
Pronormocyte	3.0 ± 0.6	3.5 ± 0.3	3.83 ± 0.50	3.83 ± 0.70	13.17 ± 0.20*

*Significant difference ($P < 0.05$) compared to the control group, $M \pm m$, $n = 6$

immature white rats, which consumed drinking water with a nitrate concentration of 50 and 150 mg/l no significant changes were noticed. The most pronounced changes were observed in white rats of the 3rd and 4th groups of both stages of maturity (both mature and immature).

Significant changes appeared in the third group of experimental rats, which consumed drinking water with nitrates at a concentration of 250 mg/l. In mature rats, there was an increase in blast cells by 2 times, rod-shaped neutrophils by 1.8 times and eosinophils by 2.4 times compared with the control group (Fig. 1).

In immature rats of the 3rd group, the number of lymphocytes (by 2.7 times) ($P < 0.05$) and eosinophils (by 2.6 times) ($P < 0.05$) were significantly increased (Fig. 2).

In the 4th group of experimental rats, which consumed drinking water with nitrates at a concentration of 500 mg/l, changes with control were most pronounced. In mature rats, the gain quantity of eosinophils by 2.8 times continued. The count of segmented neutrophils in this group increased significantly by 2.7 times compared to the control group and by 1.6 times compared to the 3rd group. The number of blasts and rod-shaped neutrophils remained significantly higher than in the control group by 2.1 and by 1.9 times, respectively (Fig. 1). In the

4th group of immature rats, the changes in the bone marrow were even greater. The percentage of eosinophils compared with the control group increased by 4.5 times and by 1.7 times compared with the 3rd group. The number of blast cells was 2.5 times higher than the control values and the number of segmented neutrophils was 1.9 times higher than the control ones (Fig. 2).

The presence of band (immature) neutrophils in circulation is termed a regenerative left shift and indicates a bone marrow response to an inflammatory stimulus. When band cells outnumber mature neutrophils in the peripheral blood, the condition is referred to as a degenerative left shift. The eosinophil has potent proinflammatory, prothrombotic and profibrotic activities. Eosinophilia can accompany a range of disorders from benign diseases to eosinophilia with organ damage to eosinophil neoplasms.

In the morphological study of red bone marrow on day 30 of the experiment, in the bone marrow sample of the control group of adult animals we found single blast cells, normocytes and granulocyte lineage cells (neutrophilic band cell and segment neutrophil) (Fig. 3). The bone marrow smear of the control group of immature individuals differed little from the same group of mature animals. In Fig. 3 (control group), there are single megakaryocytes, blast cells and normocytes and granulocyte cells.

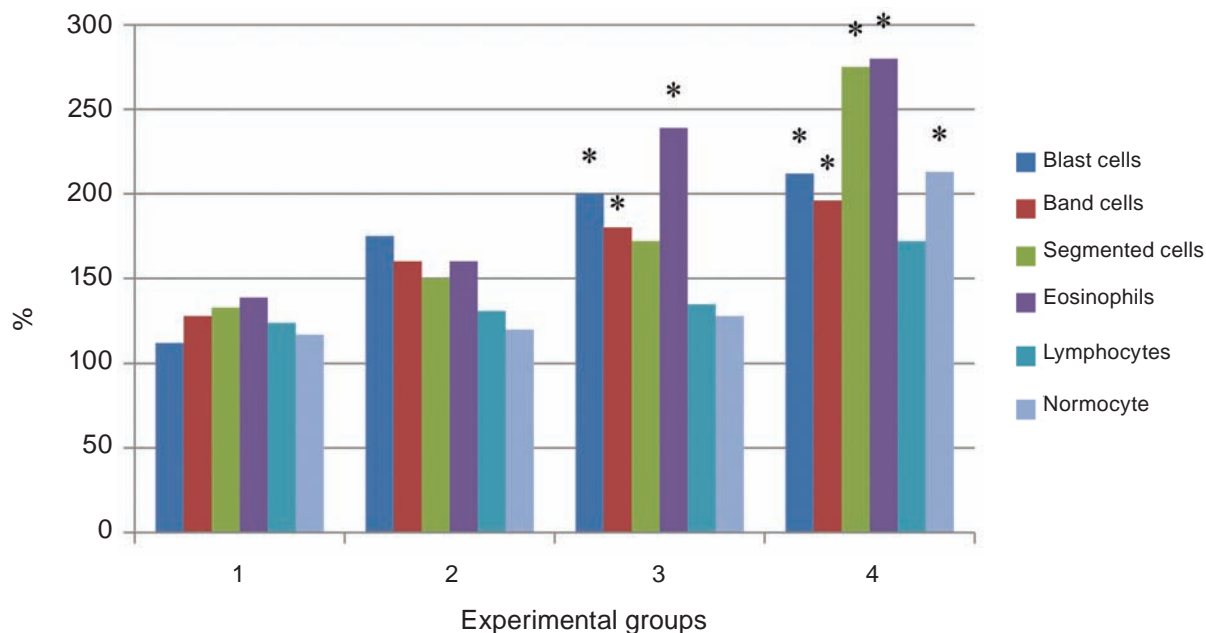


Fig. 1. Morphological composition of bone marrow of mature white female rats that consumed drinking water with nitrates (myelogram). * Significant difference ($P < 0.05$) compared to the control group, ($M \pm m$)

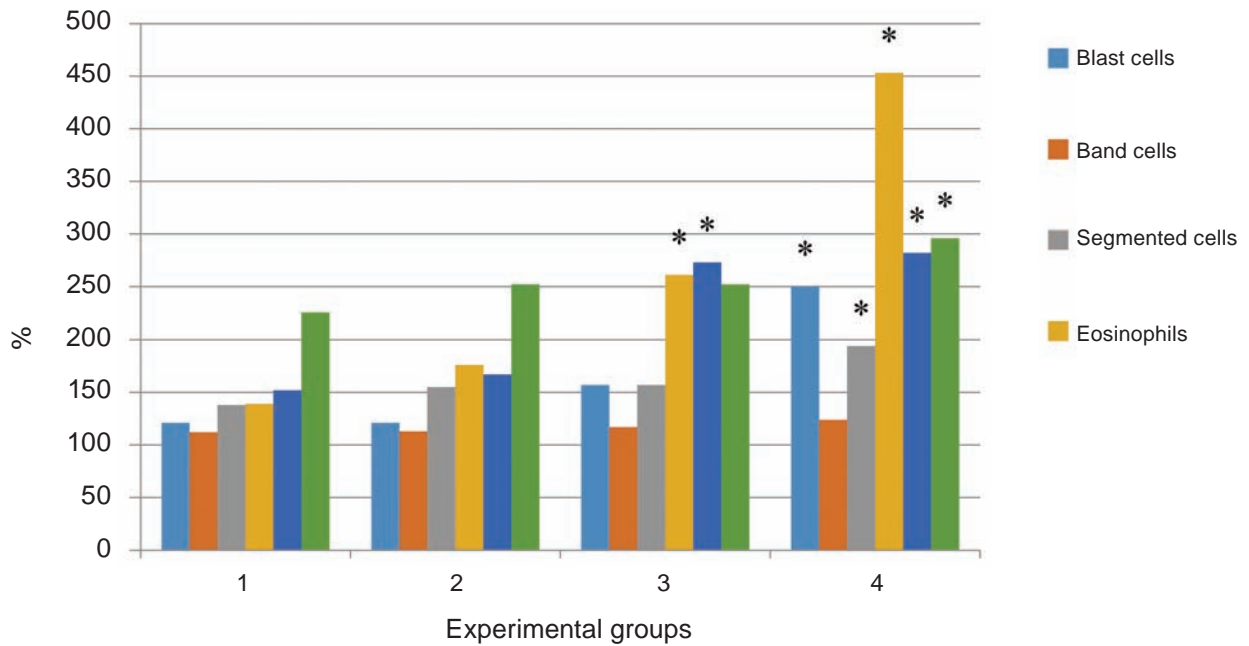


Fig. 2. Morphological composition of bone marrow of immature white female rats that consumed drinking water with nitrates (myelogram). * Significant difference ($P < 0.05$) compared to the control group, ($M \pm m$)

Hematotoxic effect of nitric acid salts was found in rats to which increased amounts of nitrates were added to the water. It should be noted that statistically significant deviations were observed starting from the 2nd experimental subgroup of mature white female rats, although some changes were observed in the 1st group.

Thus, an increase in granulocyte cells, including neutrophilic band cells (by 18%) and segmented neutrophils (by 33%), lymphocytes (by 24%), normocytes (by 17%) and blast cells (by 12%) were revealed in adult animals of the 1st subgroup, which drinking water for 30 days had nitrates at a concentration of 50 mg/l (Fig. 1). In the bone marrow of the 1st experimental subgroup of immature animals, more pronounced changes were observed including the number of blast cells increased by 24%, neutrophilic band cells and segmented neutrophils increased by 24% and by 37%, respectively, and the number of lymphocytes by 58% (Fig. 2).

We found that changes in bone marrow were more pronounced with increasing nitrate content in water. In the bone marrow samples of animals analyzed by us, the 2nd experimental subgroup of mature rats in comparison with the control group, the number of blast cells increased dramatically by 75%, normocytes increased slightly by 20%. Granulocyte sprout cells, namely segmented neutrophils

and neutrophilic band cells, increased by 50-60%, respectively, and were predominantly degeneratively altered. Single eosinophils and lymphocytes were observed (Fig. 1). We also found that NMI increased by 36.3% ($P > 0.05$) compared with the control group.

In our studies, it was found that in immature rats of the 2nd subgroup in comparison with the control group, there was an increase in the number of normocytes (by 52%), eosinophils (by 76%) and blast cells (by 21%) (Fig. 2). The NMI increased by 31.2% ($P > 0.05$) compared with the control group.

In the bone marrow smear of mature white female rats of the 3rd experimental subgroup, which consumed water with a nitrate content of 250 mg/l, the counts were most increased of eosinophils (by 139%) ($P < 0.05$) and blast cells (by 100%) ($P < 0.05$). Also, degeneratively altered granulocyte sprout cells were found in the bone marrow, the number of which increased by 70-80% ($P < 0.05$) compared to the control group. Normocytes and lymphocytes increased slightly by 28% and by 35%, respectively (Fig. 1). NMI increased by 38.1% ($P < 0.05$) compared with the control subgroup. In the 3rd subgroup of immature white rats, the number of lymphocytes increased the most (by 173%) ($P < 0.05$) and eosinophils (by 160%) ($P < 0.05$). There was an increase in the content of blast cells (by 57%). There was also a

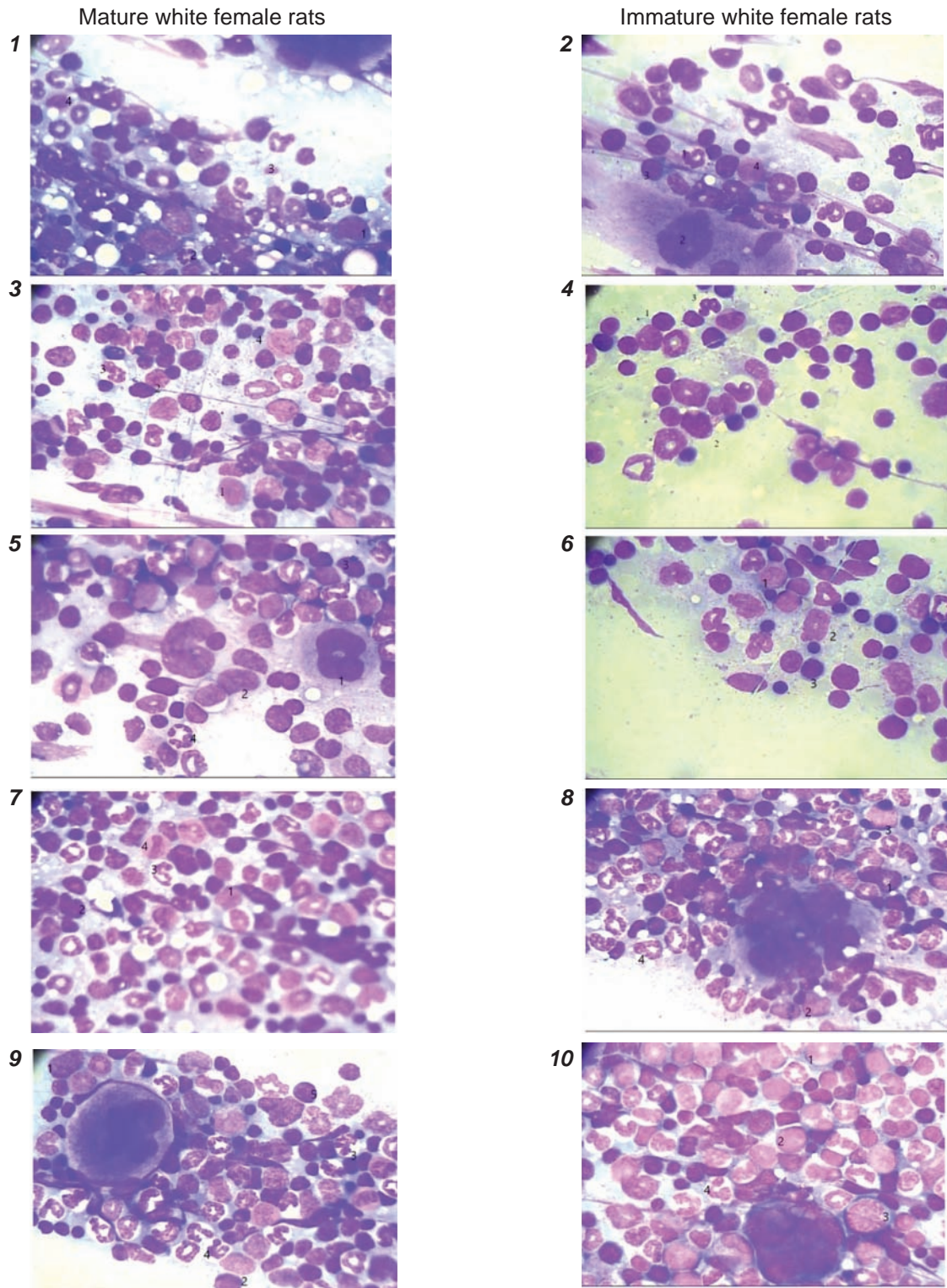


Fig. 3. Bone marrow (sternal puncture) of mature and immature white female rats that consumed drinking water with different concentrations of nitrates. 1, 2 – control subgroups mature and immature white female rats that consumed drinking water from urban water supply; 3, 4 – 1st experimental subgroups, which consumed drinking water with nitrates at a concentration of 50 mg/l; 5, 6 – 2nd experimental subgroups of white female rats that consumed drinking water with nitrates at a concentration of 150 mg/l; 7, 8 – 3rd experimental subgroup of white female rats that consumed drinking water with nitrates at a concentration of 250 mg/l; 9, 10 – 4th experimental subgroup of white female rats that consumed drinking water with nitrates at a concentration of 500 mg/l. Staining hematoxylin and eosin (magnification x700)

moderate number of degeneratively altered neutrophilic band cells and segment neutrophils, the content of which differs little from the previous group. Single megakaryocytes appear. NMI increases by 37.5% ($P < 0.05$), compared with the control group (Fig. 2).

In the 4th experimental subgroup of mature white rats, which consumed water with a nitrate content of 500 mg/l, compared with the control group, there was a significant increase by 179% ($P < 0.05$) in eosinophils and granulocyte cells, segmented neutrophils increased by 175% ($P < 0.05$) and neutrophilic band cells by 96% ($P < 0.05$). The content of blast cells and normocytes increased by 112% ($P < 0.05$). The number of lymphocytes increased by 72% (Fig. 1). The NMI was 67.2% ($P < 0.05$) higher than in the control groups.

In the 4th group of immature white rats, we found a significant increase in eosinophils by 352% ($P < 0.05$), lymphocytes and blast cells by 182% and by 150%, respectively ($P < 0.05$) compared with the control group. There was also an increase in segmented neutrophils and normocytes by almost 100%. A large number of normoblasts and megakaryocytes were observed in the bone marrow smear. Monocytes that were not observed in the control rats appeared (Fig. 2). NMI was 43.7% higher than in the control.

Summarizing the data, we suggest that drinking water with overdose nitrates, especially in concentrations of 250 and 500 mg/l (5 and 10 MAC), causes changes in the process of erythropoiesis and leucopoiesis in bone marrow (Fig. 3).

According to literary scientific sources, the main acute toxic effect of nitrates and nitrites on the hematopoietic system is the oxidation of hemoglobin to methemoglobin, which leads to severe impairment of blood oxygen capacity. This leads to a decrease in hemoglobin and erythrocytes in the peripheral blood and the activation of erythropoiesis in the bone marrow. Therefore, the growth of pronormocytes and normocytes, which are erythrocyte progenitor cells, indicates changes in the process of erythropoiesis and is compensatory. Thus, nitrate causes, in addition to the pronounced erythrotoxic (formation of methemoglobin in erythrocytes), the effect of significant changes at the stage of their formation. This may be due to their three-stage effect on the process of division and maturation of erythron, which is realized due to the direct effect of nitrates on cell function, nitrite formation with inherent cy-

totoxic effects and synthesis of nitrosamines [11]. The neutrophil maturation index, which characterizes the condition of granulocyte cells, significantly increased in the fourth experimental group (by 43.7% in immature and by 67.2% in mature), which fully confirmed active neutrophilopoiesis in the bone marrow. Increased NMI indicates delayed neutrophil maturation, increased yield of mature cells from the bone marrow and depletion of the granulocyte lineage [13, 14].

Leukopoiesis is manifested by growth in blast cells, which augment with increasing nitrate concentration in water. Blasts are precursors to the mature, circulating blood cells such as neutrophils, monocytes, lymphocytes and erythrocytes [15]. Blasts are usually found in low numbers in the bone marrow. There was also an increase in granulocyte cells, in particular in rod and segmental neutrophils.

Conclusion. The results indicate that drinking water with overdose nitrate is manifested by structural-morphological disorganization of hematopoiesis in white female rats, which is characterized by inhibition of maturation of all sprouts of hematopoietic tissue. More pronounced changes are observed in the qualitative and quantitative composition of the components of the erythrocyte sprout. These disorders are dose-dependent with an increasing hematotoxic effect of nitrates at doses of 250 and 500 mg/l in the group of immature animals. This leads to changes in the bone marrow, which in the future may cause the development of pathological processes in the body.

The identified structural changes in the bone marrow encourage the study of changes in peripheral blood in conditions of water consumption with overdoses of nitrates and support the search for effective means of correction that could be used for prophylactic purposes in practice.

Acknowledgment. We thank Cedars-Sinai Medical Center's International Research and Innovation in Medicine Program, and the Association for Regional Cooperation in the Fields of Health, Science and Technology (RECOOP HST Association) for their support.

Conflict of interest. Authors have completed the Unified Conflicts of Interest form at http://ukr-biochemjournal.org/wp-content/uploads/2018/12/coi_disclosure.pdf and declare no conflict of interest

Funding. The research was supported by I. Horbachevsky Ternopil National Medical University.

ВПЛИВ НІТРАТІВ НА КІСТКОВИЙ МОЗОК ЩУРІВ

М. В. Данчишин[✉], О. В. Лотоцька

Тернопільський національний медичний університет ім. І. Я. Горбачевського МОЗ України;
✉ e-mail: danchyshyn@tdmu.edu.ua

Забруднення підземних вод нітратами в останні роки зростає. Метою дослідження було визначення морфологічних особливостей кісткового мозку щурів за умов споживання питної води з різним вмістом нітратів. Експеримент проводили на 2 групах білих самок-щурів різного віку (статевозрілих та статевонезрілих) по 30 особин у кожній. Обидві групи було розділено на 5 підгруп, які відрізнялися за якістю питної води, яку вони споживали самостійно. Протягом 30 днів щурам давали нітрати у питній воді в дозі 50, 150, 250, 500 мг нітрату натрію на літр. Тварини контрольної групи пили воду з міського водопроводу. Оцінювали вплив нітратів на кістковий мозок щурів за допомогою морфологічних досліджень. Встановлено, що вживання щурами питної води з нітратами змінює еритропоез та лейкопоез, про що свідчило зростання бластів, лімфоцитів, пронормоцитів та нормоцитів, мегакаріоцитів та еозинофілів, зміщення клітин паростків еритроцитів. Показано підвищення індексу дозрівання нейтрофілів, збільшення виходу зрілих клітин з кісткового мозку та виснаження гранулоцитарного ряду. Більш виражені зміни спостерігалися в якісному та кількісному складі компонентів паростка еритроцита. Ці розлади були дозозалежними із посиленням гематотоксичної дії нітратів у дозах 250 та 500 мг/л у статевонезрілих тварин і призводили до змін у кістковому мозку, що в подальшому може спричинювати розвиток патологічних процесів в організмі.

Ключові слова: нітрати, питна вода, кістковий мозок щурів, фарбування за Ван Гізоном.

References

1. Yao X, Yin N, Faiola F. Stem cell toxicology: a powerful tool to assess pollution effects on human health. *Natl Sci Rev*. 2016; 3(4): 430-450.
2. Tavian M, Réault B. Embryonic development of the human hematopoietic system. *Int J Dev Biol*. 2005; 49(2-3): 243-250.
3. Hirschi KK. Hemogenic endothelium during development and beyond. *Blood*. 2012; 119(21): 4823-4827.
4. Travlos GS. Histopathology of bone marrow. *Toxicol Pathol*. 2006; 34(5): 566-598.
5. Ward MH, Jones RR, Brender JD, de Kok TM, Weyer PJ, Nolan BT, Villanueva CM, van Breda SG. Drinking Water Nitrate and Human Health: An Updated Review. *Int J Environ Res Public Health*. 2018; 15(7): 1557.
6. Lototska OV, Prokopov VO. Assessment of the risk of consumption of drinking water with high content of nitrates on the health of the population of Ternopil region. *Environ Health*. 2018; (4(89)): 20-24. (In Ukrainian).
7. Fossen Johnson S. Methemoglobinemia: Infants at risk. *Curr Probl Pediatr Adolesc Health Care*. 2019; 49(3): 57-67.
8. Brender JD, Weyer PJ. Agricultural Compounds in Water and Birth Defects. *Curr Environ Health Rep*. 2016; 3(2): 144-152.
9. Singh S, Anil AG, Kumar V, Kapoor D, Subramanian S, Singh J, Ramamurthy PC. Nitrates in the environment: A critical review of their distribution, sensing techniques, ecological effects and remediation. *Chemosphere*. 2022; 287(Pt 1): 131996.
10. Kryvetskyi V, Herasymiuk I, Kryvetska I. Morphological peculiarities of rat bone marrow under the influence of nitrate salts in increased concentrations. *Clin Anat Oper Surg*. 2019; 18(4): 6-10. (In Ukrainian).
11. Gluhcheva Y, Ivanov I, Petrova E, Pavlova E, Vladov I. Sodium nitrite-induced hematological and hemorheological changes in rats. *Ser Biomechan*. 2012; 27(3-4): 53-58.
12. Berchanu ShM. Clinical hematology. Bucharest: Medizdat, 1985. 1222 p. (In Russian).
13. Mostovoy YuM, Sidorov AA. Analyzes: normative indicators, interpretation of changes. Handbook for students and doctors. Kyiv: DZK Center, 2016. 96 p. (In Ukrainian).
14. Lapovets LE, Lebed GB, Yastremskaya OO, Lutsyk BD, Porokhnavevets LE, Akimova VM, Zaletsky MP. Selected lectures on laboratory medicine. Part 1. Hematological studies. Lviv: Publishing House FOP Kraevsky RP, 2014. 342 p. (In Ukrainian).
15. Vareniuk IM, Dzerzhynskyi ME. Methods of cyto-histological diagnosis: Tutorial. Kyiv: Interservice, 2019. 256 p. (In Ukrainian).